



Degenerative changes of the sacroiliac joint after spinal fusion: an evidence-based systematic review

Umile Giuseppe Longo[†], Mattia Loppini[†], Alessandra Berton[†],
Luca Laverde[†], Nicola Maffulli^{‡,§,*}, and Vincenzo Denaro[†]

[†]Department of Orthopaedic and Trauma Surgery, Campus Biomedico University, Via Alvaro del Portillo, 200, Rome 00155, Italy, [‡]Department of Musculoskeletal Disorders, University of Salerno School of Medicine and Surgery, Salerno, Italy, and [§]Centre for Sports and Exercise Medicine, Queen Mary University of London, Barts and the London School of Medicine and Dentistry, Mann Ward Mile End Hospital, Bancroft Road, London, UK

*Correspondence address: Department of Musculoskeletal Disorders, University of Salerno School of Medicine and Surgery, Salerno, Italy. E-mail: n.maffulli@qmul.ac.uk

Accepted 15 September 2014

Abstract

Introduction: The rate of fusion surgery of the lumbar spine has remarkably increased over the past 30 years.

Sources of data: We performed a comprehensive search of studies addressing the assessment of sacroiliac joint (SIJ) after lumbar spinal fusion surgery on PubMed, OVID/Medline, Cochrane, CINAHL, Google scholar and Embase.

Areas of agreement: The fusion of spinal segments leads to degenerative changes in the mobile segments above or below the fused spine, because of the increase of the stresses imposed on the adjacent levels.

Areas of controversy: There is no consensus about prevalence and potential risk factors contributing to SIJ degenerative changes in patients undergoing fusion surgery.

Growing points: Studies using radiographic evaluation to detect degenerative changes of the SIJ are being performed.

Areas timely for developing research: No definitive estimation about the prevalence of degenerative changes of the SIJ after fusion surgery can be provided. Further studies are required to identify the risk factors involved in post-fusion degenerative changes of the SIJ.

Key words: spinal fusion, sacroiliac joint, degeneration, osteoarthritis, pain

Introduction

Lumbar spinal fusion surgery has advanced greatly in the last few decades, allowing the management of several spine disorders, including degenerative, traumatic and oncological pathologies. The rate of fusion surgery of the lumbar spine has remarkably increased over the past 30 years.^{1,2} Although lumbar spinal fusion surgery can be associated with good clinical outcomes for the management of the underlying spine disease, some reasons for concern still remain regarding the potential long-term consequences of these procedures.

Fusion of spinal segments leads to the adjacent segment disease (ASD), consisting of degenerative changes in the levels adjacent to the fusion.³ The biomechanical changes of the spine after fusion surgery result in the increase of loads on the adjacent levels, leading to increased intradiscal pressure, increased facet loading and greater motion at the adjacent segments.⁴

The sacrum is the lowest segment of the spine. It articulates with the iliac bones through the sacroiliac joint (SIJ). When the spine fusion procedure includes the sacrum, the SIJ is the adjacent distal joint to the fusion. For this reason, the biomechanical changes from surgery also involve the SIJ and may determine the development of degenerative changes. ‘Failed back surgery syndrome’ (FBSS) is characterized by persistent or recurrent low back pain (LBP) and/or lower limb pain after lumbar fusion.⁵ In lumbar spine surgery, the incidence of FBSS varies from 10 to 40%;^{6–9} however, failure rates depend on the surgical procedure performed, with higher rates for operations with instrumentation. Although several aetiologies can be identified, failure associated with involvement of the SIJ has been estimated in 32%¹⁰ to 37%¹¹ of patients. However, to our knowledge, no comprehensive review addressing degenerative changes of the SIJ after lumbar spinal fusion surgery has been performed.

This systematic review determined the prevalence and the potential risk factors contributing to

degenerative changes of the SIJ in patients who have undergone lumbar spinal fusion surgery.

Materials and methods

Literature searching and data collection

A review of the literature was performed in a systematic fashion using the preferred reporting items for systematic reviews and meta-analyses (PRISMA) checklist and algorithm.^{12–20} To identify the studies addressing the assessment of SIJ after lumbar spinal fusion surgery, the following databases were screened over the years 1966–2014: PubMed, OVID/Medline, Cochrane, CINAHL, Google scholar and Embase. The following keywords were combined together to perform the search: ‘sacroiliac joint’ in combination with ‘osteoarthritis’, ‘pain’, ‘dysfunction’, ‘spine fusion’, ‘Failed Back Surgery Syndrome’ and ‘adjacent segment disease’. All potentially eligible articles were retrieved, and their references were assessed by the reviewers by hand to identify further relevant articles, including reviews and meta-analyses.

Papers reporting on the assessment of SIJ after lumbar spinal fusion and published in peer-reviewed journals were included. Each included study was examined to extract data on characteristics of patients, length of follow-up, preoperative diagnosis, surgical procedure, fused levels, methods for the assessment of SIJ and degeneration rate of SIJ. Case reports and articles missing clinical and imaging assessment of the SIJ were excluded. We resolved disagreements by discussion.

Results

A total of 506 references were identified searching of the literature and scanning the reference section of the various articles. Of those, 484 were excluded because the abstract showed that they did not deal with the topic at hand and/or did not comply with the inclusion criteria (Fig. 1).

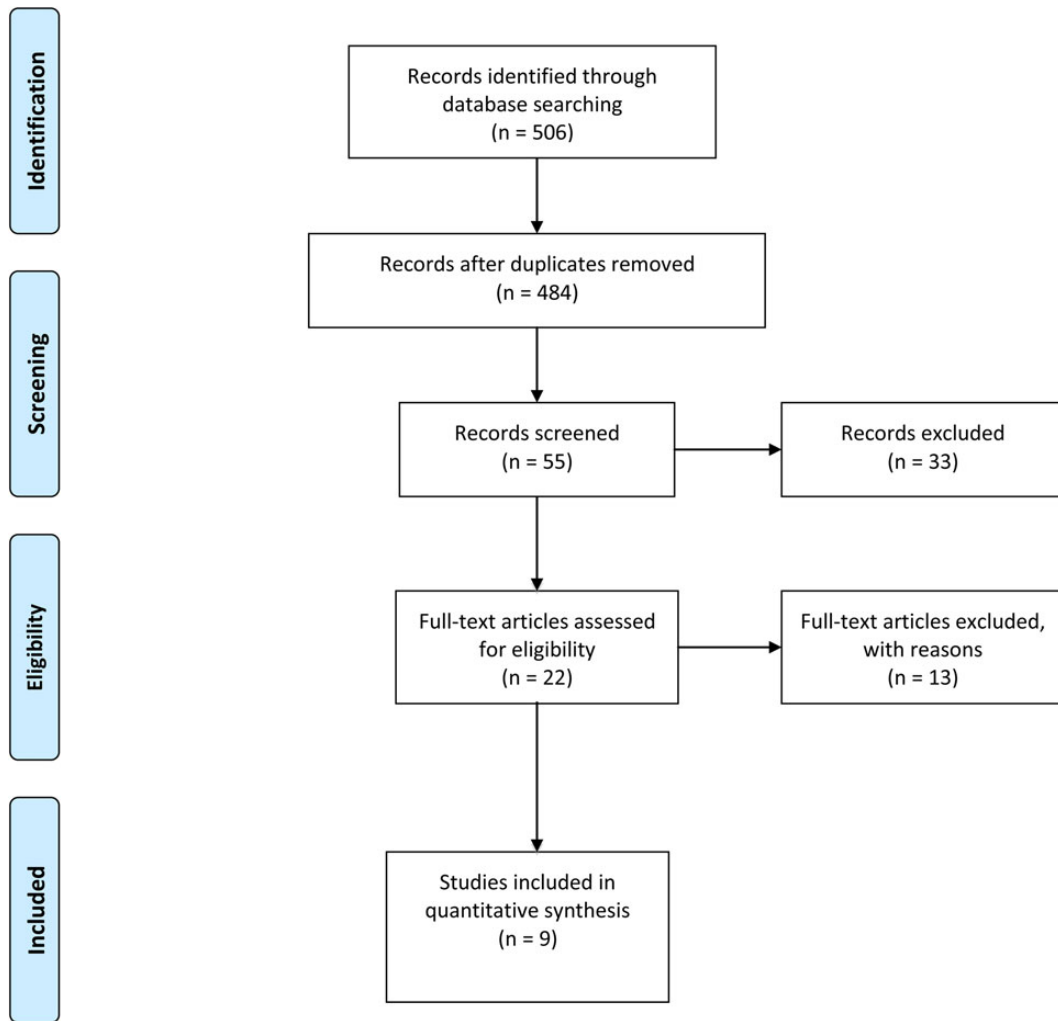


Fig. 1 PRISMA 2009 flow diagram.

The evaluation of remaining full-text papers resulted in the exclusion of further 13 articles,^{21–33} because no data on the spinal surgery procedure and/or assessment of the SIJ were provided. Finally, we included nine articles, describing patients who underwent lumbar spinal fusion surgery and assessment of SIJ after the procedure (Table 1).

Demographics

The number of included patients who underwent spine fusion was 364, including 167 (46%) males and 197 (54%) females. The mean age of patients was 51.6 years (range 11–86) at the time of the index

procedure. The mean follow-up for the postoperative assessment of patients was 5.5 years (range 1–11.9).

Diagnosis

Only five^{11,34–37} of the included studies, describing 222 patients, provided details on the preoperative diagnosis. They reported: disc herniation in 123 (56%) subjects, recurrent disc herniation in 6 (3%), spondylolisthesis in 26 (12%), spinal stenosis in 32 (14%), scoliosis in 5 (2%), vertebral fracture in 3 (1%) and LBP with or without irradiation in 27 (12%). In 142 patients, the preoperative diagnosis was unknown.^{5,10,38,39}

Table 1 Details of the included studies

Authors, years	Study design (level of evidence)	Number of patients (M:F)	Mean age (SD or range) (years)	Preoperative diagnosis	Surgical procedure	Fused levels	Mean follow-up (SD or range)	Assessment of SIJ joint	SIJ degeneration
Frymoyer <i>et al.</i> (1978)	Retrospective comparative study (III)	Group 1: (fusion) 95 (60:35); 1A without donor site pain (60) and 1B with donor site pain (35); Group 2: (no spinal fusion) 36 (18:18)	Group 1: 38.7 (9.3); Group 2: 44 (10.3)	DH (131)	Group 1: disc excision and posterior fusion (PF) with autologous posterior iliac bone graft (PIBG); Group 2: laminectomy and disc excision	Lumbosacral fusion	13.7 years	Imaging: X-ray in AP, static and dynamic lateral views (131)	Left SIJ: G1A 23%, G1B 20%, G2 14%; right SIJ: G1A 16%, G1B 6%, G2 14%
Even-Sapir <i>et al.</i> (1994)	Retrospective case series (IV)	33 (17:16); early group (surgery < 4 years) 9 (6:3); late group (surgery > 4 years) 24 (11:13)	46.6 (22–69); early group: 41.1 (22–67); late group: 48.75 (28–69)	Early group: DH (5); spondylolisthesis L5-S1 (2); recurrent DH (2); late group: DH (9); spondylolisthesis L5-S1 (5); recurrent DH (3); spinal stenosis (2); scoliosis (3); fracture (2)	Lateral fusion (LF) (21); PF (9); anterior fusion (AF) and PF (3) Early group: LF (8); PF (1); Late group: LF (13); PF (8); AF and PF (3)	Early group: L4-S1 (6), L5-S1 (2), L3-L5 (1); Late group: L4-S1 (16), L4-L5 (3), L3-L5 (3), T12-L4 (1), L3-S1 (1), L3-L4 (1), L1-S1 (1)	Early group: 17.8 months (8–42); Late group: 11.9 years (5–30)	Imaging: bone scintigraphy (33), SPECT (33), X-ray in AP and lateral views (30), X-ray in dynamic lateral view (4), CT scan (16), MRI (3)	Increased uptake of SIJ: 76%
Ebraheim <i>et al.</i> (1999)	Retrospective comparative study (III)	22 (6:16); Group 1 (no SIJ violation) 3 (1:2); Group 2 (ligamentous violation) 16 (3:13); Group 3 (synovial violation) 16 (3:13)	55.9 (26–85); Group 1: 54.6 (35–77) Group 2: 55.5 (26–85) Group 3: 59.3 (44–73)	DH (10); spondylolisthesis (7); spinal stenosis (5)	PF with autologous PIBG	–	3.8 years (2–9)	Diagnostic intra-articular injection (22); imaging: CT scan (22)	Group 1: 0; Group 2: mild degenerative changes in 62.5%; Group 3: severe degenerative changes in 100%
Gates <i>et al.</i> (1999)	Retrospective case series (IV)	63 (37:26) Group 1: (fusion) 28 (19:9); Group 2: (no fusion) 35 (18:17)	53.6 (28–83); males: 52.8 (28–82); females: 54.8 (33–83)	–	Laminectomy (28); laminectomy with fusion (10); laminectomy with fusion plus metallic appliances (7); fusion without laminectomy (7); discectomy (7); laminectomy with fusion and removal of metallic devices (3); fusion plus metallic devices without	–	>2 years (<i>n</i> = 32); 1–2 years (<i>n</i> = 15); <1 year (<i>n</i> = 16)	Imaging: SPECT (63), X-ray in AP and lateral views (38), CT scan (16), MRI (22), myelography (<i>n</i> = 6), positron emission tomography (<i>n</i> = 7)	Increased uptake of SIJ: Group 1: 25%; Group 2: 14.2%

Katz <i>et al.</i> (2003)	Retrospective case series (IV)	34 (13:21)	54 (30–81)	–	laminectomy (1). Types of fusion: PF (24); posterolateral fusion (PLF) (2); AF (3); LF (1)	CF (11); anterior lumbar interbody fusions with posterior transpedicular instrumentation (3); anterior lumbar interbody fusion (7); PLF (10); posterior lumbar interbody fusion (1); not known (2). Donor site: autologous PIBG (8); local bone (24); unknown (2)	L5-S1 (8); from L4 to the sacrum (14); from L3 to the sacrum (6); from L2 to the sacrum (2); thoracolumbosacral fusion (4)	5 years (7 months–32 years)	Clinical assessment: physical examination (34); diagnostic evaluation: SIJ block (34)	SIJ pain 32%, probable SIJ pain 29%
Maigne <i>et al.</i> (2005)	Prospective case series (IV)	40 (14:26)	48 (11)	LBP with or without irradiation (27); DH (4); L5–S1 spondylolisthesis (3); lumbar stenosis (3); lumbar scoliosis (2); fracture (1)	PLF with (34) or without (2) instrumentation; ALF (4)	L2-L4 (2); L3-L4 (1); L3-L5 (3); L4-L5 (8); L2-S1 (2); L3-S1 (4); L4-S1 (8); L5-S1 (12)	3.8 years (3.7)	Clinical assessment: physical examination (40); imaging: bone scintigraphy or SPECT (40); diagnostic evaluation: SIJ block (40)	SIJ pain 35%	
Ha <i>et al.</i> (2008)	Prospective comparative study (II)	Intervention group: 32 (10:22); Group 1 (floating fusion) 22 (7:15); Group 2 (fixed fusion) 10 (3:7) Control group: 34 (18:16)	Intervention group: 64 (53–78); Group 1: 65.6 (56–78); Group 2: 60.5 (53–68); Control group: 64.5 (60–69)	Spinal stenosis (22); spondylolisthesis (9); recurrent DH (1)	PLF (26) or posterior lumbar interbody fusion (6) with instrumentation and autologous PIBG	Group 1: L4-L5 (7), L3-L5 (15); Group 2: L5-S1 (4), L4-S1 (6)	87.6 months (77–94)	Clinical assessment: visual analogue scale (66); functional assessment: Oswestry disability index score (66); imaging: CT scan (66)	Intervention group: 75%, control group: 38.2% ($P = 0.02$); G1: 64%, G2: 100% ($P = 0.02$); one-segment fusion: 91%, two-segment fusion: 67%; G1 one-segment fusion: 86%, two-segment fusion: 53%; G2: 100%	
DePalma <i>et al.</i> (2011)	Retrospective comparative study (III)	170 (58:112); Group 1: (fusion) 28 (14:14); Group 2: (no fusion) 141 (44:141)	52.3 (15.3) Group 1: 56.3 (13.7) Group 2: 54 (16.7)	–	Fusion incorporating anterior construct (4); PLF without anterior construct (23); Harrington rod (1)	L2-L5 (2); L3-L5 (2); L4-L5 (5); L2-S1 (2); L3-S1 (4); L4-S1 (5); L5-S1 (6); T-L4 (2)	Group 1: 12 months (5.5–60) Group 2: 12 months (6–24.5)	Clinical assessment: SIJ provocative manoeuvres (170); diagnostic evaluation: SIJ block	SIJ pain: G1 42.9%, G2 12.8% ($P = 0.0005$); SIJ pain: fusion to sacrum 58.8%, fusion to lumbar spine 18.2% ($P < 0.0001$)	

Continued

Table 1 Continued

Authors, years	Study design (level of evidence)	Number of patients (M:F)	Mean age (SD or range) (years)	Preoperative diagnosis	Surgical procedure	Fused levels	Mean follow-up (SD or range)	Assessment of SIJ joint	SIJ degeneration
Liliang <i>et al.</i> (2011)	Prospective cohort study (II)	52 (14:38)	63 (11.5; 38–86)	–	Instrumented lumbar fusion to the sacrum (20) or lumbar fusion without S1 (32) with autologous PIBG (10) or bone graft from other site (spinal processes, lamina or allograft) (42)	1 level (21); 2 levels (21); >2 levels (10)	–	Clinical assessment: Patrick's test, Gaenslen's test, Shear test, Yeoman manoeuvre, standing extension test, palpation of sacroiliac ligaments (52); diagnostic evaluation: SIJ block (52)	SIJ pain 40.3%

Surgery

Eight^{5,10,11,34–38} of the included studies, describing 312 patients, reported an adequate description of the fusion procedure. The spine fusion was posterior in 158 (51%), posterolateral in 95 (30%), lateral in 22 (7%), anterior in 14 (5%), anterior and posterior in 6 (2%), anterolateral in 4 (1%) and circumferential in 11 (4%) subjects. In two patients, the type of spine fusion was unknown.

Seven^{5,10,11,35–37,39} of the included studies provided details on the extension of the spine fusion. Of 314 fusion procedures, 222 (71%) were lumbosacral fusions, 85 (27%) lumbar, 4 (1%) thoracolumbosacral and 3 (1%) thoracolumbar.

Five^{10,11,34,36,39} of the included studies reported data on the source of the bone graft used for the fusion. Of 235 fusion procedures, 167 (71%) patients received autologous posterior iliac crest bone graft, 24 (10%) patients received autologous morselized local bone and the type of graft was unknown in 44 (19%) patients.

Clinical and functional outcomes

Scoring systems to evaluate clinical and functional outcomes were used in only one³⁶ of the included studies. Pain was assessed with the visual analogue scale, whereas the Oswestry disability index score was performed to assess physical function.

Clinical assessment of sacroiliac joint

Clinical assessment of the SIJ with physical examination and SIJ provocative manoeuvres was performed in 296 of 364 patients (81.3%).^{5,10,37,39}

Imaging

The radiographic assessment was performed in 199 of 364 patients (54.7%),^{11,35,38} including anteroposterior, static and dynamic lateral views of the lumbosacral spine. On the other hand, computed tomography (CT) scans were performed in 120 of 364 patients (33%),^{34–36,38} whereas magnetic resonance imaging (MRI) was performed in 25 of 364 patients (6.8%).^{35,38} Single photon emission computed tomography (SPECT) and/or bone scintigraphy were performed in 169 of 364 patients (46.4%).^{35,37,38} Finally,

assessment of the SIJ with diagnostic injections was performed in 318 of 364 patients (87.3%).^{5,10,34,37,39}

Degeneration of sacroiliac joint

Only three^{11,34,36} of the included studies evaluated the degenerative changes of SIJ after lumbar spinal fusion with plain radiographs or CT scan. At radiographic evaluation, the prevalence of degenerative changes was reported up to 42%.¹¹ At CT imaging, Ha *et al.*³⁶ reported a prevalence of 75% after fusion and 38.2% in controls ($P = 0.02$). Moreover, in patients who underwent fusion, the prevalence of degenerative changes was 64% for lumbar fusions and 100% for lumbosacral fusions ($P = 0.02$). Ebrahim *et al.*³⁴ showed different rates of degenerative changes, depending on the violation of SIJ. Mild degenerative changes occurred in 62.5% of patients with a ligamentous violation of SIJ, and severe degenerative changes in 100% of patients with a synovial violation of SIJ. No degenerative changes were found in patients without violation of SIJ.

Four studies^{5,10,37,39} evaluated the SIJ involvement in terms of SIJ pain diagnosed with injections. The overall prevalence of SIJ pain after lumbar spinal fusion, regardless the extension of fusion, ranged from 32%¹⁰ to 43%.⁵ DePalma *et al.*⁵ compared the prevalence of SIJ pain in patients with and without fusion, reporting a prevalence of 43 and 12.8% ($P = 0.0005$), respectively. Moreover, the authors showed a significant difference in the rate of prevalence of pain between patients with fusion to the sacrum (58.8%) and fusion to the lumbar spine (18.2%) ($P < 0.0001$).

Finally, the remaining two studies^{35,38} used SPECT and/or bone scintigraphy, showing an increased uptake of SIJ from 25 to 76% of patients after fusion. Gates *et al.*³⁸ reported a higher prevalence of increased uptake at the SIJ in patients with fusion than patients who had undergone spine surgery without fusion (25 vs 14.2%).

Discussion

The present systematic review aimed to determine the prevalence of the SIJ degenerative changes after lumbar spinal fusion surgery and to identify the potential risk factors contributing to it.

The SIJ is a diarthrodial joint with a fibrous capsule containing synovial fluid.⁴⁰ Its articular surfaces present hyaline cartilage on the sacral side and fibrocartilage on the iliac side; the latter has less favourable mechanical characteristics and seems to be more susceptible to degenerative changes.⁴¹

The sacrum is the lowest segment of the spine and is wedge-shaped in both the coronal and transverse planes. It is locked between the iliac bones and is able to transfer forces from the trunk to the lower extremities through the SIJ. Although possible, the movements of the SIJ are quite limited by the adjacent ligaments.^{42,43} The most predominant movements include rotation up to 5°, and translation <2 mm.⁴⁴ Finally, the SIJ is more susceptible to axial compression and rotational stresses, but more resistant to lateral forces when compared with the lumbar spine segment.^{45,46}

The current published literature does not allow to provide a definitive estimation on the occurrence of the SIJ degenerative changes after lumbar spinal fusion surgery: the heterogeneity of the published studies prevents to perform a pooling data analysis. Only three^{11,34,36} studies evaluated the degenerative changes of the SIJ with imaging exams, such as plain radiographs and CT scan. At radiographic evaluation, the prevalence of degenerative changes was reported up to 42%,¹¹ whereas it was 75% at CT imaging.³⁶ This variability may well result from the higher sensitivity of CT scanning to detect degenerative changes of the SIJ.

Among the studies evaluating the involvement of the SIJ with diagnostic injections,^{5,10,37,39} the overall prevalence of SIJ pain after lumbar spinal fusion ranged from 32%¹⁰ to 43%.⁵ Although we can hypothesize that pain can be determined by degenerative changes secondary to an increased functional load at the SIJ after surgery, the authors did not correlate symptoms with imaging findings; thus, it is not possible to estimate the real prevalence of SIJ degenerative changes after lumbar spinal fusion. Indeed, two different conditions should be distinguished: adjacent segment degenerative changes and ASD.⁴ The first one indicates the changes, detected at imaging, of the joint adjacent to the index level, regardless the presence of symptoms; the second one indicates clinical symptoms secondary to the degenerative changes of the adjacent

joint evident at imaging.⁴ As joint degeneration can be asymptomatic, the involvement of the SIJ detected at diagnostic injections was underestimated, as shown by the higher prevalence of the SIJ pathology with CT imaging.

Another limitation is that none of the five studies providing data on the preoperative diagnosis reported a preoperative assessment of the SIJ. However, Sembrano and Polly⁴⁷ reported that among patients referred to a spine clinic for LBP, 15% of them have SIJ pathology in combination or not with spine pathology. Therefore, we could hypothesize that some patients with postoperative degeneration of SIJ could be already affected by SIJ pathology before surgery. In this respect, the role of lumbar and lumbosacral fusion surgery in determining SIJ pathology could be overestimated. Finally, a further limitation is that the included studies did not provide data regarding the period of time after surgery to develop SIJ degeneration.

Some potential risk factors for degenerative changes of the SIJ can be identified, but further investigations are required to define their actual significance. One of the most important is the inclusion of sacrum in the fusion. Ha *et al.*³⁶ reported an almost doubled prevalence of degenerative changes of the SIJ after fusion when compared with controls (75 vs 38.2%). Moreover, in the fusion group all the patients undergoing lumbosacral fusion exhibited degenerative changes of the SIJ, while these changes were present in 64% of patients with lumbar fusion.

The role of the number of fusion segments remains unclear. Some authors suggest that the higher number of vertebrae involved results in higher stress forces at the adjacent segment, leading to greater risk of joint degenerative changes.^{30,48} However, other authors did not confirm these findings.^{11,49,50} For example, Ha *et al.*³⁶ did not find any association between the number of fused vertebrae in the lumbar spine and osteoarthritis of the SIJ.

The harvest of the posterior part of the iliac crest has been identified as further risk factor. Ebraheim *et al.*³⁴ reported severe degenerative changes in all patients with a violation of SIJ at the time of the bone graft harvest. To avoid iatrogenic injury to the joint, the authors suggest to harvest a segment of iliac crest located proximal to the posterior superior

iliac spine.⁵¹ Although Ebraheim *et al.*³⁴ did not identify degenerative changes in patients without violation of SIJ, Ha *et al.*³⁶ reported joint degeneration associated with cancellous bone harvesting from the posterior superior iliac spine, despite no evidence of joint damage being present at CT scan. The authors referred this phenomenon as pelvic instability induced by the harvest of cancellous bone.

In conclusion, the SIJ is affected by lumbar and lumbosacral fusion surgery with the SIJ pain reported up to 43%, and the degeneration of SIJ at imaging assessment is reported in up to 75%. Although no definitive estimation about the prevalence of degenerative changes of the SIJ after lumbar spinal fusion surgery can be provided, it seems to be higher than what reported in studies using diagnostic injections. Some factors determine an increased risk of developing SIJ degenerative changes, including fusion extended to the sacrum and bone graft harvesting from the posterior iliac crest. Finally, we recommend to perform a comprehensive assessment of the SIJ including physical examination, joint injections, conventional radiographs and accurate imaging exams, such as CT scan, to detect early degenerative changes in asymptomatic patients who have an increased risk to develop an ASD in the future.

Conflicts of interest statement

None declared.

References

1. Deyo RA, Nachemson A, Mirza SK. Spinal-fusion surgery—the case for restraint. *N Engl J Med* 2004;350:722–6.
2. Davis H. Increasing rates of cervical and lumbar spine surgery in the United States, 1979–1990. *Spine* 1994;19:1117–23; discussion 1123–4.
3. Park P, Garton HJ, Gala VC, et al. Adjacent segment disease after lumbar or lumbosacral fusion: review of the literature. *Spine* 2004;29:1938–44.
4. Harrop JS, Youssef JA, Maltenfort M, et al. Lumbar adjacent segment degeneration and disease after arthrodesis and total disc arthroplasty. *Spine* 2008;33:1701–7.
5. DePalma MJ, Ketchum JM, Saullo TR. Etiology of chronic low back pain in patients having undergone lumbar fusion. *Pain Med* 2011;12:732–9.

6. Lehmann TR, LaRocca HS. Repeat lumbar surgery. A review of patients with failure from previous lumbar surgery treated by spinal canal exploration and lumbar spinal fusion. *Spine* 1981;6:615–9.
7. Law JD, Lehman RA, Kirsch WM. Reoperation after lumbar intervertebral disc surgery. *J Neurosurg* 1978;48:259–63.
8. North RB, Campbell JN, James CS, et al. Failed back surgery syndrome: 5-year follow-up in 102 patients undergoing repeated operation. *Neurosurgery* 1991;28:685–90; discussion 690–1.
9. Gehrchen PM, Dahl B, Katonis P, et al. No difference in clinical outcome after posterolateral lumbar fusion between patients with isthmic spondylolisthesis and those with degenerative disc disease using pedicle screw instrumentation: a comparative study of 112 patients with 4 years of follow-up. *Eur Spine J* 2002;11:423–7.
10. Katz V, Schofferman J, Reynolds J. The sacroiliac joint: a potential cause of pain after lumbar fusion to the sacrum. *J Spinal Disord Tech* 2003;16:96–9.
11. Frymoyer JW, Howe J, Kuhlmann D. The long-term effects of spinal fusion on the sacroiliac joints and ilium. *Clin Orthop Relat Res* 1978;134:196–201.
12. Moher D, Liberati A, Tetzlaff J, et al. Preferred reporting items for systematic reviews and meta-analyses: the PRISMA statement. *BMJ* 2009;339:b2535.
13. Liberati A, Altman DG, Tetzlaff J, et al. The PRISMA statement for reporting systematic reviews and meta-analyses of studies that evaluate healthcare interventions: explanation and elaboration. *BMJ* 2009;339:b2700.
14. Longo UG, King JB, Denaro V, et al. Double-bundle arthroscopic reconstruction of the anterior cruciate ligament: does the evidence add up? *J Bone Joint Surg Br* 2008;90:995–9.
15. Maffulli N, Longo UG, Spiezia F, et al. Aetiology and prevention of injuries in elite young athletes. *Med Sport Sci* 2011;56:187–200.
16. Longo UG, Loppini M, Denaro L, et al. Rating scales for low back pain. *Br Med Bull* 2010;94:81–144.
17. Longo UG, Loppini M, Romeo G, et al. Errors of level in spinal surgery: an evidence-based systematic review. *J Bone Joint Surg Br* 2012;94:1546–50.
18. Longo UG, Loppini M, Rizzello G, et al. Glenoid and humeral head bone loss in traumatic anterior glenohumeral instability: a systematic review. *Knee Surg Sports Traumatol Arthrosc* 2014;22:392–414.
19. Longo UG, Loppini M, Rizzello G, et al. Latarjet, Bristow, and Eden-Hybinette procedures for anterior shoulder dislocation: systematic review and quantitative synthesis of the literature. *Arthroscopy* 2014;30:1184–1211.
20. Longo UG, Loppini M, Rizzello G, et al. Management of primary acute anterior shoulder dislocation: systematic review and quantitative synthesis of the literature. *Arthroscopy* 2014;30:506–22.
21. Lee CS, Hwang CJ, Lee SW, et al. Risk factors for adjacent segment disease after lumbar fusion. *Eur Spine J* 2009;18:1637–43.
22. Edwards CC 2nd, Bridwell KH, Patel A, et al. Thoracolumbar deformity arthrodesis to L5 in adults: the fate of the L5-S1 disc. *Spine (Phila Pa 1976)* 2003;28:2122–31.
23. Lee CK. Accelerated degeneration of the segment adjacent to a lumbar fusion. *Spine (Phila Pa 1976)* 1988;13:375–7.
24. Tsuchiya K, Bridwell KH, Kuklo TR, et al. Minimum 5-year analysis of L5-S1 fusion using sacropelvic fixation (bilateral S1 and iliac screws) for spinal deformity. *Spine* 2006;31:303–8.
25. Hambly MF, Wiltse LL, Raghavan N, et al. The transition zone above a lumbosacral fusion. *Spine (Phila Pa 1976)* 1998;23:1785–92.
26. Anandjiwala J, Seo JY, Ha KY, et al. Adjacent segment degeneration after instrumented posterolateral lumbar fusion: a prospective cohort study with a minimum five-year follow-up. *Eur Spine J* 2011;20:1951–60.
27. Booth KC, Bridwell KH, Eisenberg BA, et al. Minimum 5-year results of degenerative spondylolisthesis treated with decompression and instrumented posterior fusion. *Spine (Phila Pa 1976)* 1999;24:1721–7.
28. Kim KT, Lee SH, Lee YH, et al. Clinical outcomes of 3 fusion methods through the posterior approach in the lumbar spine. *Spine (Phila Pa 1976)* 2006;31:1351–7; discussion 1358.
29. Korovessis P, Papazisis Z, Koureas G, et al. Rigid, semi-rigid versus dynamic instrumentation for degenerative lumbar spinal stenosis: a correlative radiological and clinical analysis of short-term results. *Spine (Phila Pa 1976)* 2004;29:735–42.
30. Rahm MD, Hall BB. Adjacent-segment degeneration after lumbar fusion with instrumentation: a retrospective study. *J Spinal Disord* 1996;9:392–400.
31. Etebar S, Cahill DW. Risk factors for adjacent-segment failure following lumbar fixation with rigid instrumentation for degenerative instability. *J Neurosurg* 1999;90:163–9.
32. Kuslich SD, Danielson G, Dowdle JD, et al. Four-year follow-up results of lumbar spine arthrodesis using the Bagby and Kuslich lumbar fusion cage. *Spine (Phila Pa 1976)* 2000;25:2656–62.
33. Wu Y, Tang H, Li Z, et al. Outcome of posterior lumbar interbody fusion versus posterolateral fusion in lumbar degenerative disease. *J Clin Neurosci* 2011;18:780–3.

34. Ebraheim NA, Elgafy H, Semaan HB. Computed tomographic findings in patients with persistent sacroiliac pain after posterior iliac graft harvesting. *Spine* 2000;25:2047–51.
35. Even-Sapir E, Martin RH, Mitchell MJ, et al. Assessment of painful late effects of lumbar spinal fusion with SPECT. *J Nucl Med* 1994;35:416–22.
36. Ha KY, Lee JS, Kim KW. Degeneration of sacroiliac joint after instrumented lumbar or lumbosacral fusion: a prospective cohort study over five-year follow-up. *Spine* 2008;33:1192–8.
37. Maigne JY, Planchon CA. Sacroiliac joint pain after lumbar fusion. A study with anesthetic blocks. *Eur Spine J* 2005;14:654–8.
38. Gates GF, McDonald RJ. Bone SPECT of the back after lumbar surgery. *Clin Nucl Med* 1999;24:395–403.
39. Liliang PC, Lu K, Liang CL, et al. Sacroiliac joint pain after lumbar and lumbosacral fusion: findings using dual sacroiliac joint blocks. *Pain Med* 2011;12:565–70.
40. Mirkovic S, Abitbol JJ, Steinman J, et al. Anatomic consideration for sacral screw placement. *Spine* 1991;16:S289–94.
41. McGregor M, Cassidy JD. Post-surgical sacroiliac joint syndrome. *J Manipulative Physiol Ther* 1983;6:1–11.
42. Frigerio NA, Stowe RR, Howe JW. Movement of the sacroiliac joint. *Clin Orthop Relat Res* 1974;100:370–7.
43. Wilder DG, Pope MH, Frymoyer JW. The functional topography of the sacroiliac joint. *Spine* 1980;5:575–9.
44. Stureson B, Selvik G, Uden A. Movements of the sacroiliac joints. A roentgen stereophotogrammetric analysis. *Spine* 1989;14:162–5.
45. Forst SL, Wheeler MT, Fortin JD, et al. The sacroiliac joint: anatomy, physiology and clinical significance. *Pain Physician* 2006;9:61–7.
46. Dreyfuss P, Dreyer SJ, Cole A, et al. Sacroiliac joint pain. *J Am Acad Orthop Surg* 2004;12:255–65.
47. Sembrano JN, Polly DW Jr. How often is low back pain not coming from the back? *Spine (Phila Pa 1976)* 2009;34:E27–32.
48. Penta M, Sandhu A, Fraser RD. Magnetic resonance imaging assessment of disc degeneration 10 years after anterior lumbar interbody fusion. *Spine* 1995;20:743–7.
49. Nagata H, Schendel MJ, Transfeldt EE, et al. The effects of immobilization of long segments of the spine on the adjacent and distal facet force and lumbosacral motion. *Spine* 1993;18:2471–9.
50. Wiltse LL, Radecki SE, Biel HM, et al. Comparative study of the incidence and severity of degenerative change in the transition zones after instrumented versus noninstrumented fusions of the lumbar spine. *J Spinal Disord* 1999;12:27–33.
51. Xu R, Ebraheim NA, Yeasting RA, et al. Anatomic considerations for posterior iliac bone harvesting. *Spine* 1996;21:1017–20.